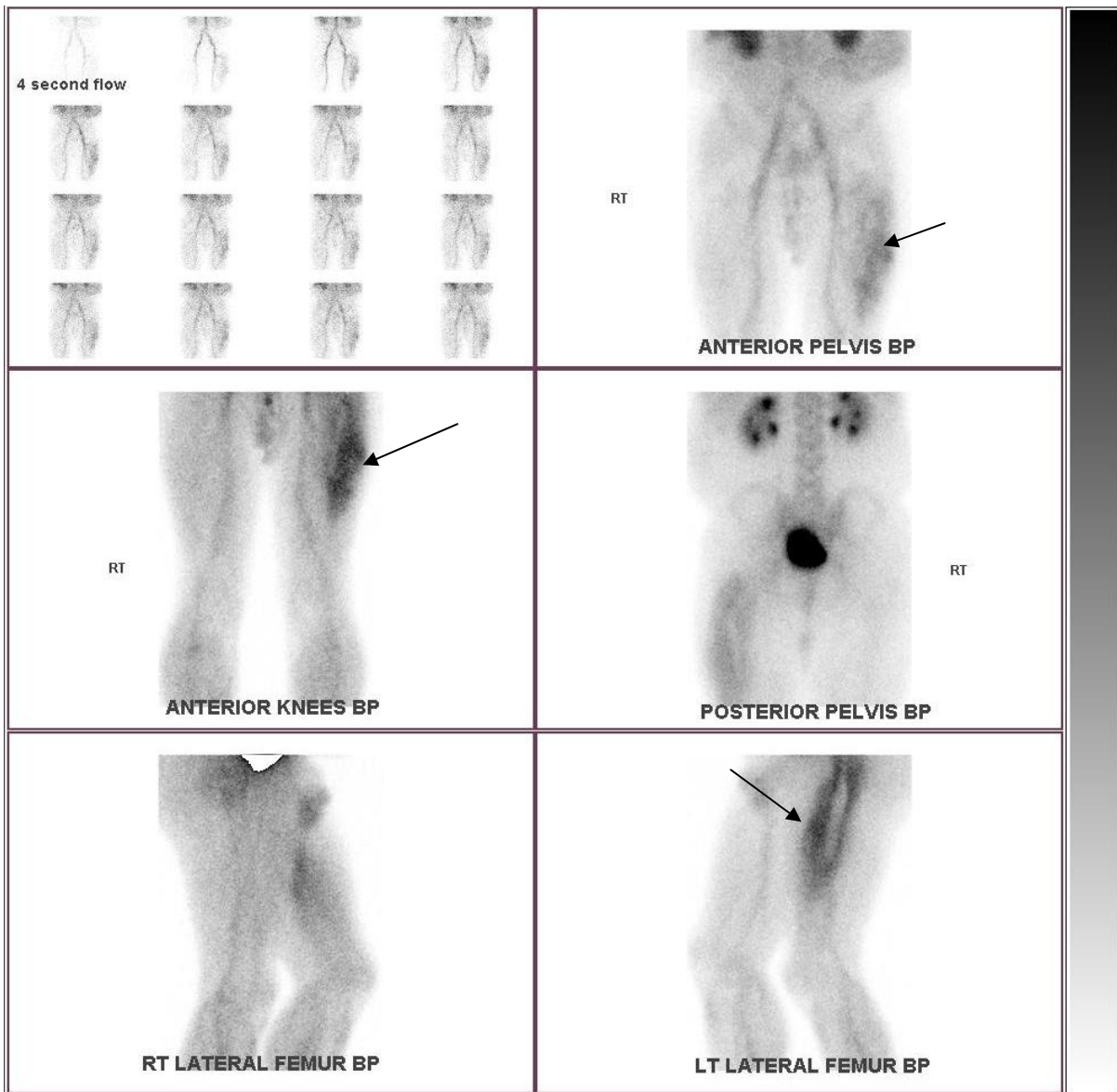


**OLD ORGANISING HEAMATOMA SIMULATING A VASCULAR TUMOUR  
OR INFLAMMATORY/ INFECTIVE PATHOLOGY**



63 yo male with pain left thigh for 3 months, wakes patient at night. Relevant PH includes

Lt #NOF with p/plate 4 yrs ago and colorectal cancer 5 yrs ago.

In the early images (above) there was marked increased vascularity and intense hyperaemia of the lateral left thigh.

In the delayed images (below) there was only faint bone tracer uptake in the soft tissue of the lateral left thigh.

The DD included soft tissue tumour or an inflammatory lesion.

At open surgery the vastus lateralis muscle contained old haemorrhagic tissue surrounded by fibrosis.

Histology found a large old haematoma with secondary inflammation.

