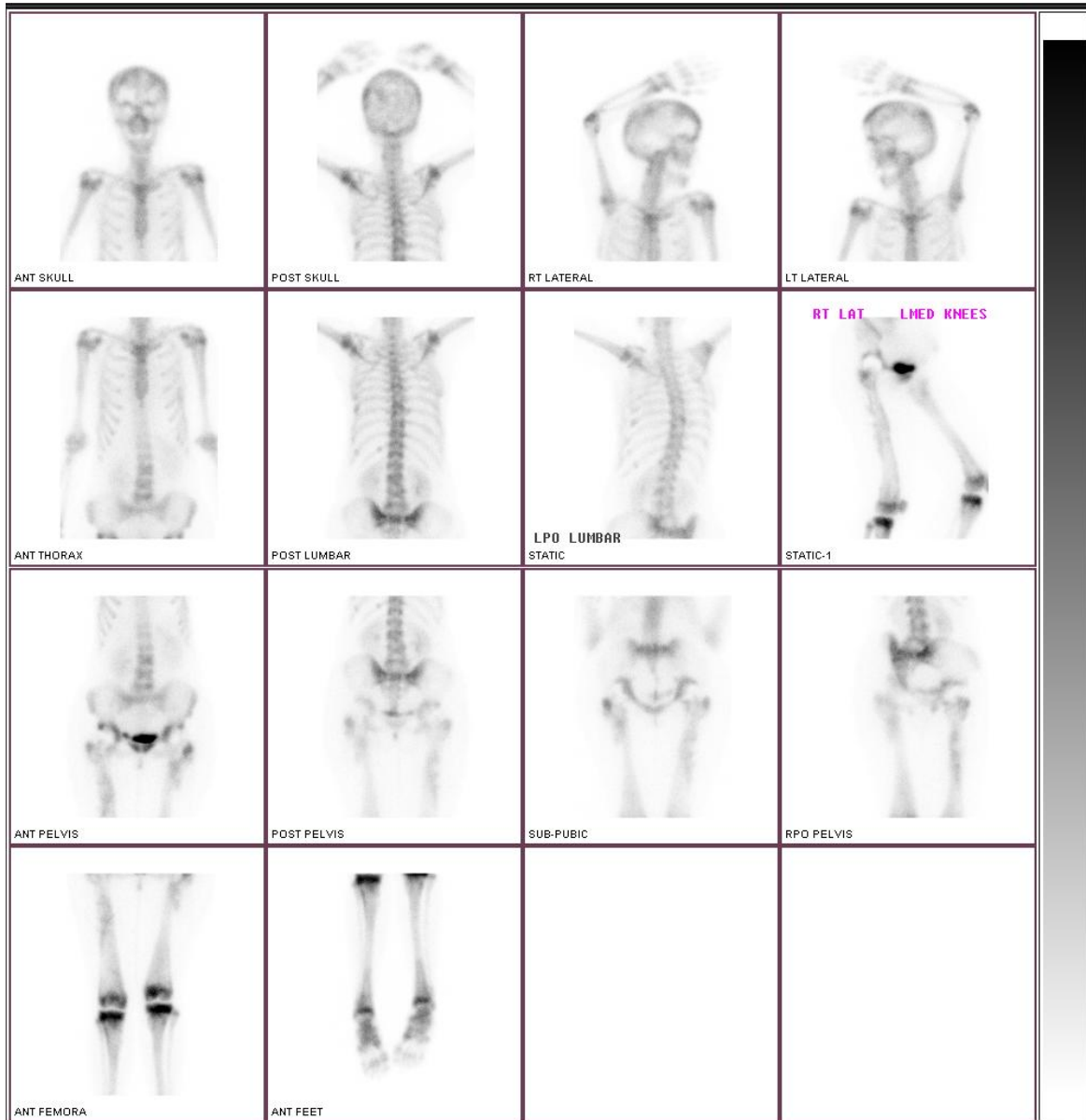


OSTEOPETROSIS



A 40year old female presented with known osteopetrosis and a history of multiple fractures. The last known fracture was of the sacrum 2 years ago. Previous bilateral THR's are noted. Patient presented with right side SIJ pain.

Whole body bone scan shows early right acetabular loosening and bilateral trochanteric bursitis. There are multiple, old healed fractures of the thoracic and lumbar spine, left side ribs posteriorly and the femurs. The major joints periarticular and excess sternal uptake are consistent with expanded bone marrow and metabolic bone disease. All of the above findings are consistent with osteopetrosis.