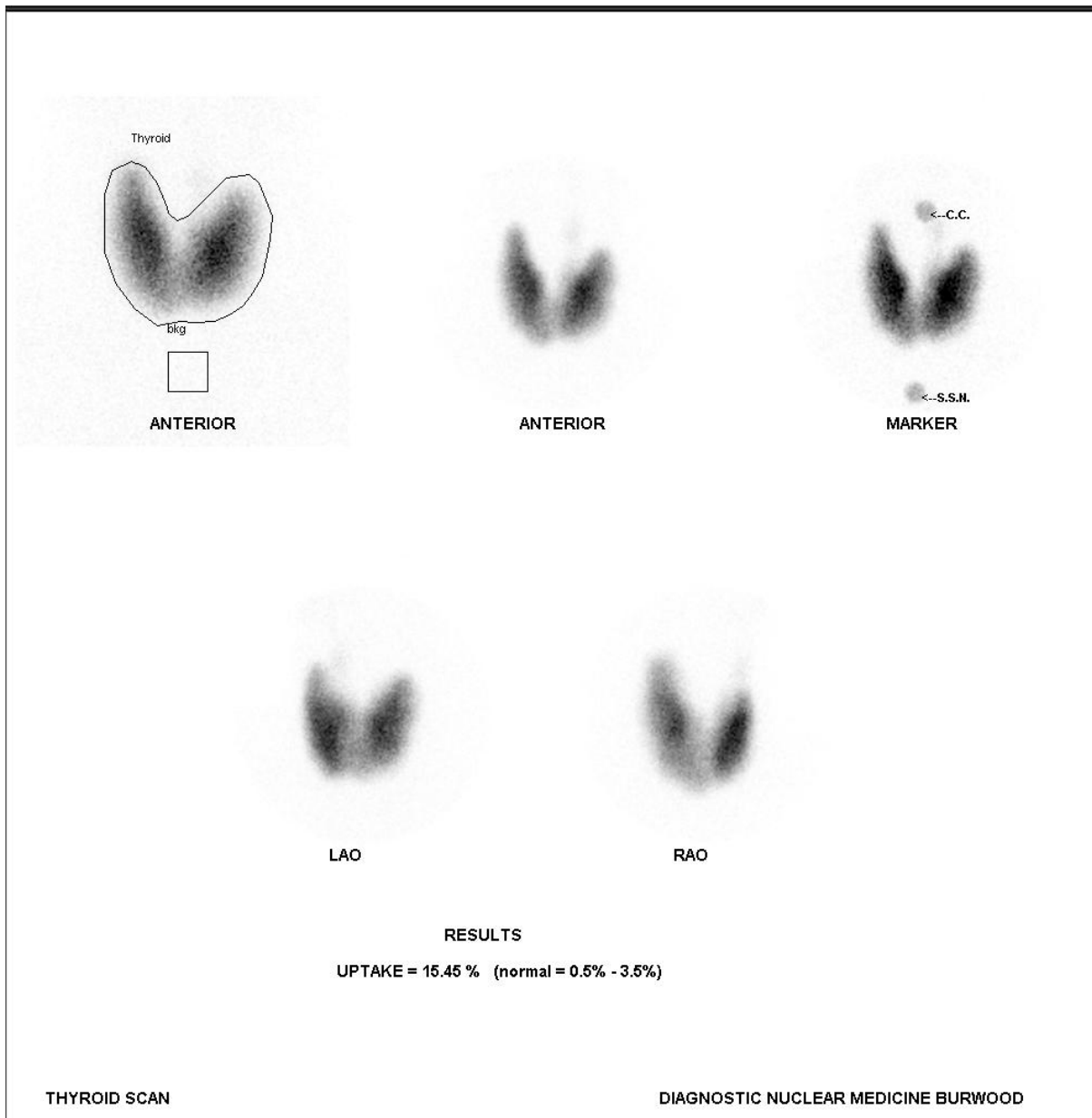


GRAVE'S DISEASE



28 yo male presented with tremor, palpitations and loss of weight.

No current medications. TFT's elevated.

The thyroid gland was normal in position and size. There was uniform, increased uptake throughout the gland.

The thyroid uptake at 20 minutes was 15.4%. The normal range = 0.5-3.5%.

The findings were consistent with Grave's disease. The differential diagnosis is thyroiditis which can have a similar clinical picture and biochemistry but treatment is very different.