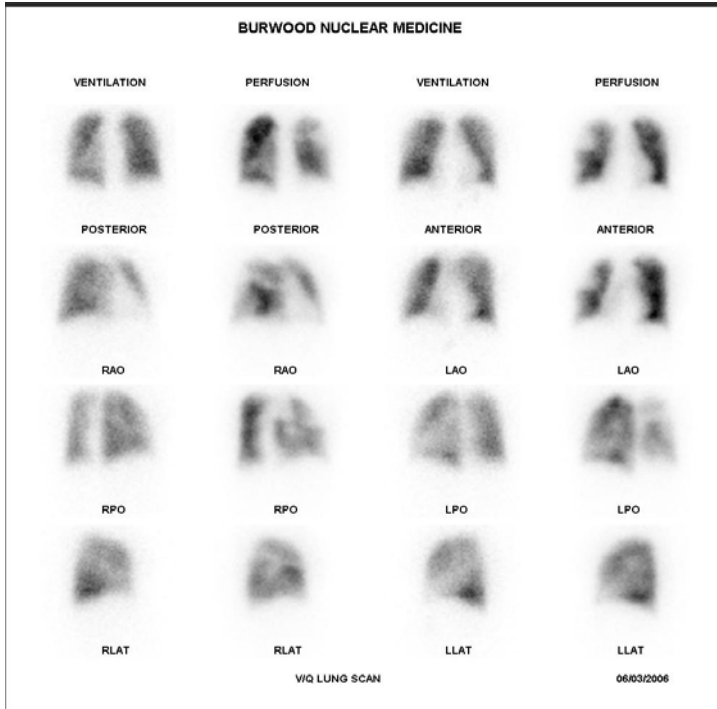


MULTIPLE PULMONARY EMBOLI

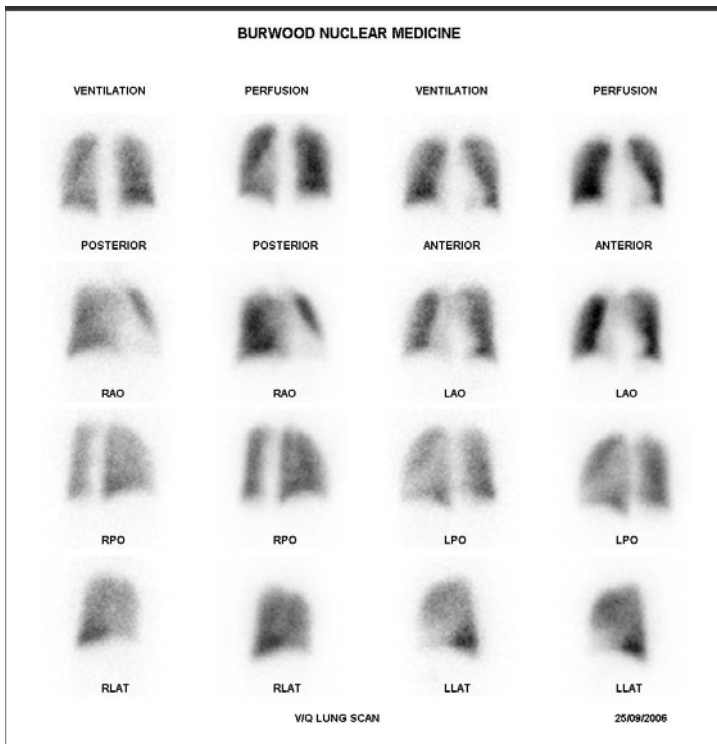


INITIAL STUDY

A 48 yo female presented with a 5 day history of SOB and vague inframammary chest pain and a painful, swollen left leg. She had recently commenced HRT for menopause symptoms.

A VQ scan showed multiple, mismatched perfusion defects in both lungs, predominantly in the right lung.

The follow-up study 5 weeks after commencing anticoagulants showed complete resolution of the mismatched defects and no interval embolism.



FOLLOW-UP STUDY