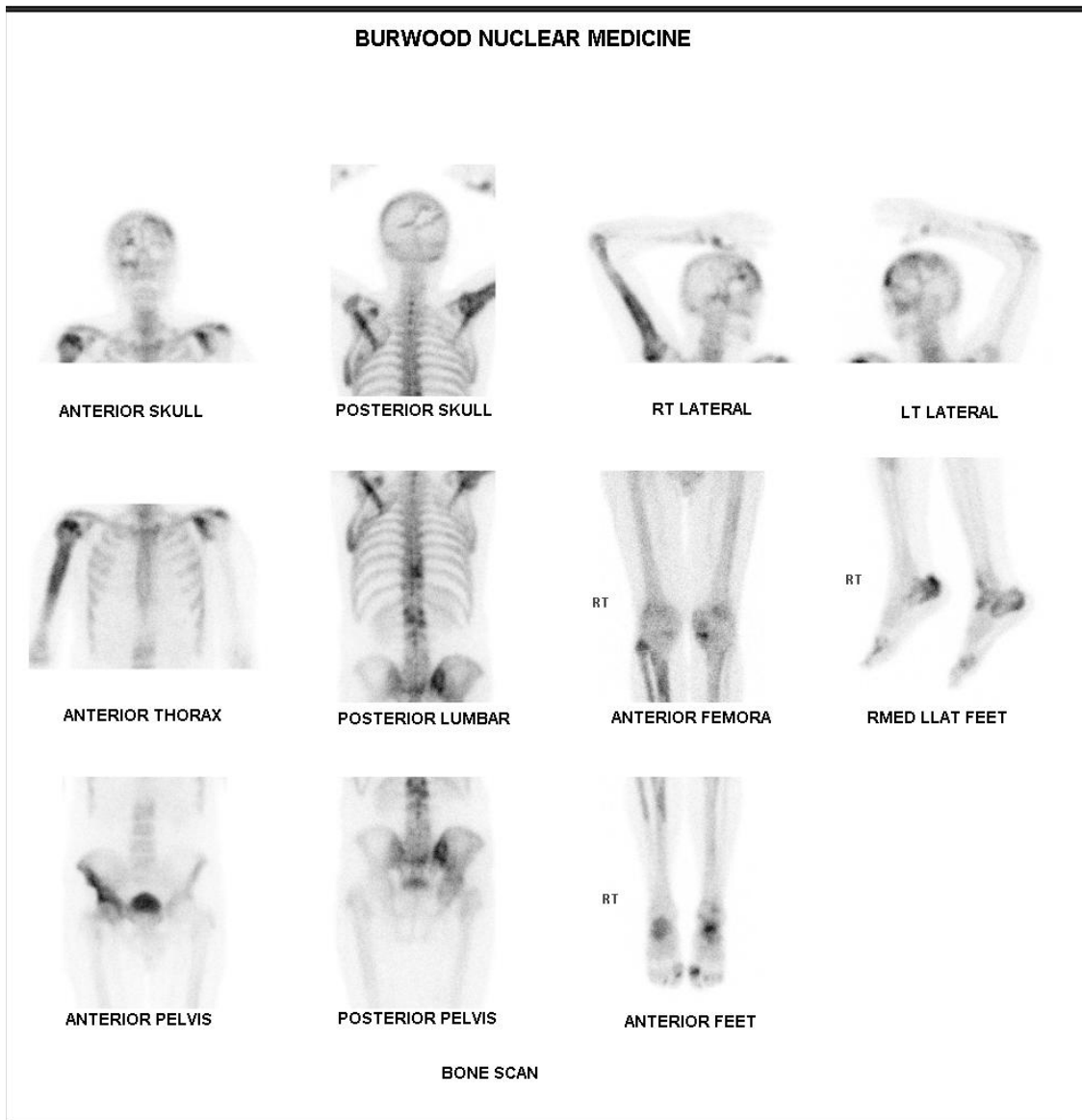


WIDESPREAD POLYOSTOTIC PAGET'S DISEASE



A 76yo male asymptomatic, with a history of known polyostotic Paget's disease. Recent commencement of therapy.

There is axial and appendicular skeletal involvement with intense tracer accumulation in the Pagetoid bones.