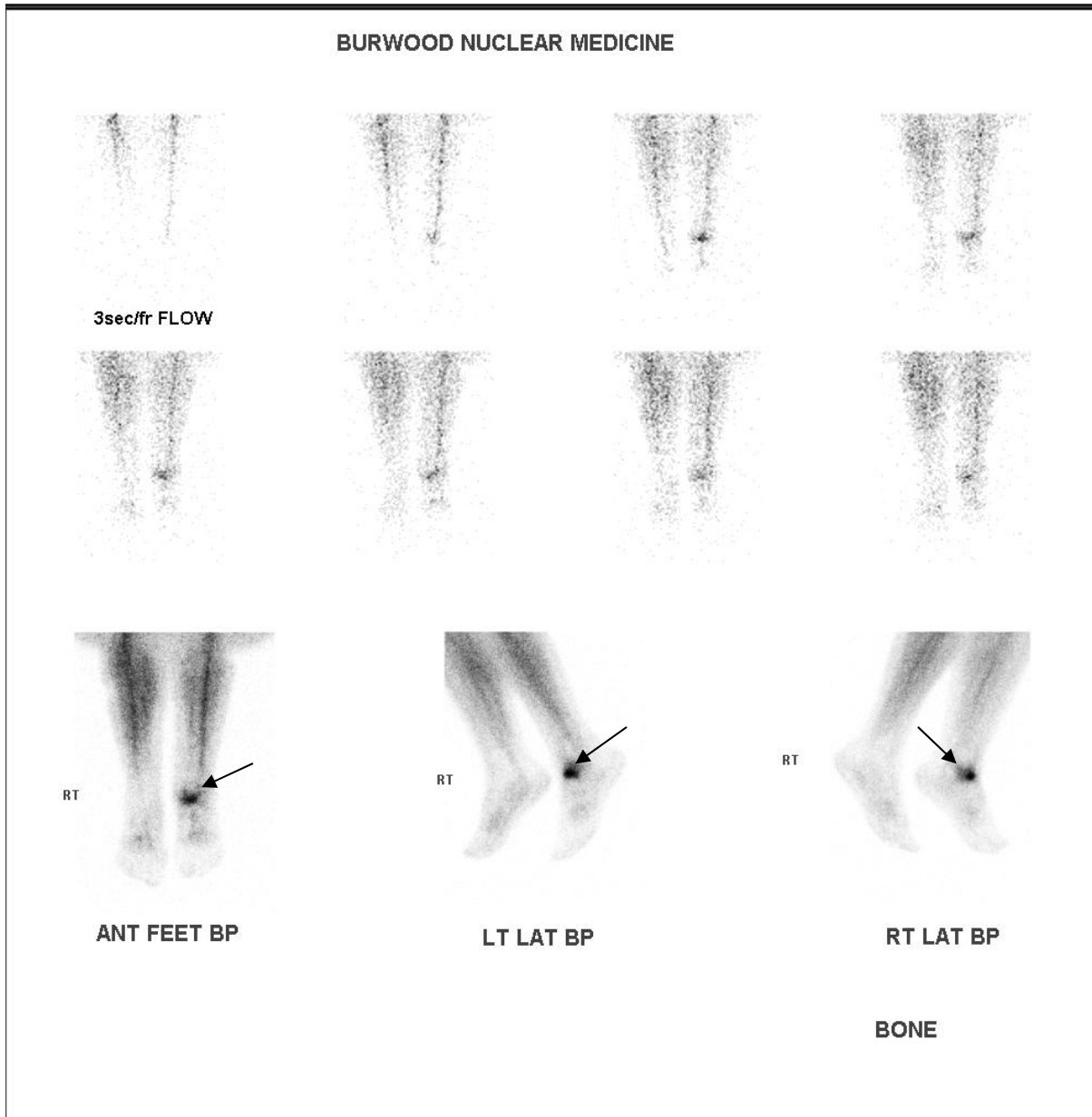
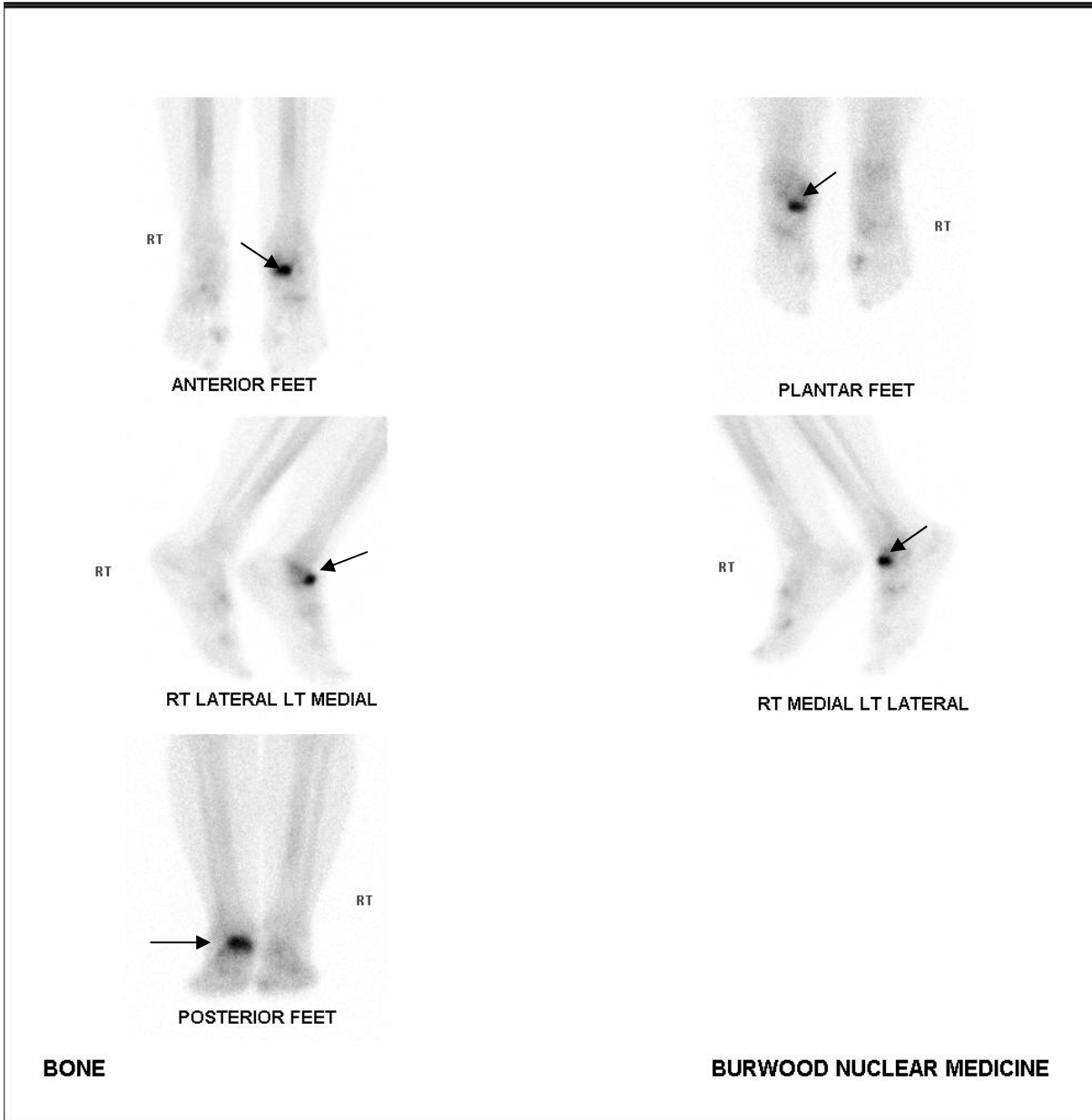


HEAD OF TALUS FRACTURE



55yo female presents with a recent twisting injury of the left ankle and foot, four weeks prior.

In the early images there was increased vascularity and increased hyperaemia of the head of the left talus (arrows above).



In the delayed images there was intense abnormal uptake of the head of the left talus. Mild arthritis is noted in the right 1st MTP joint and left 2nd & 3rd TMT joints.