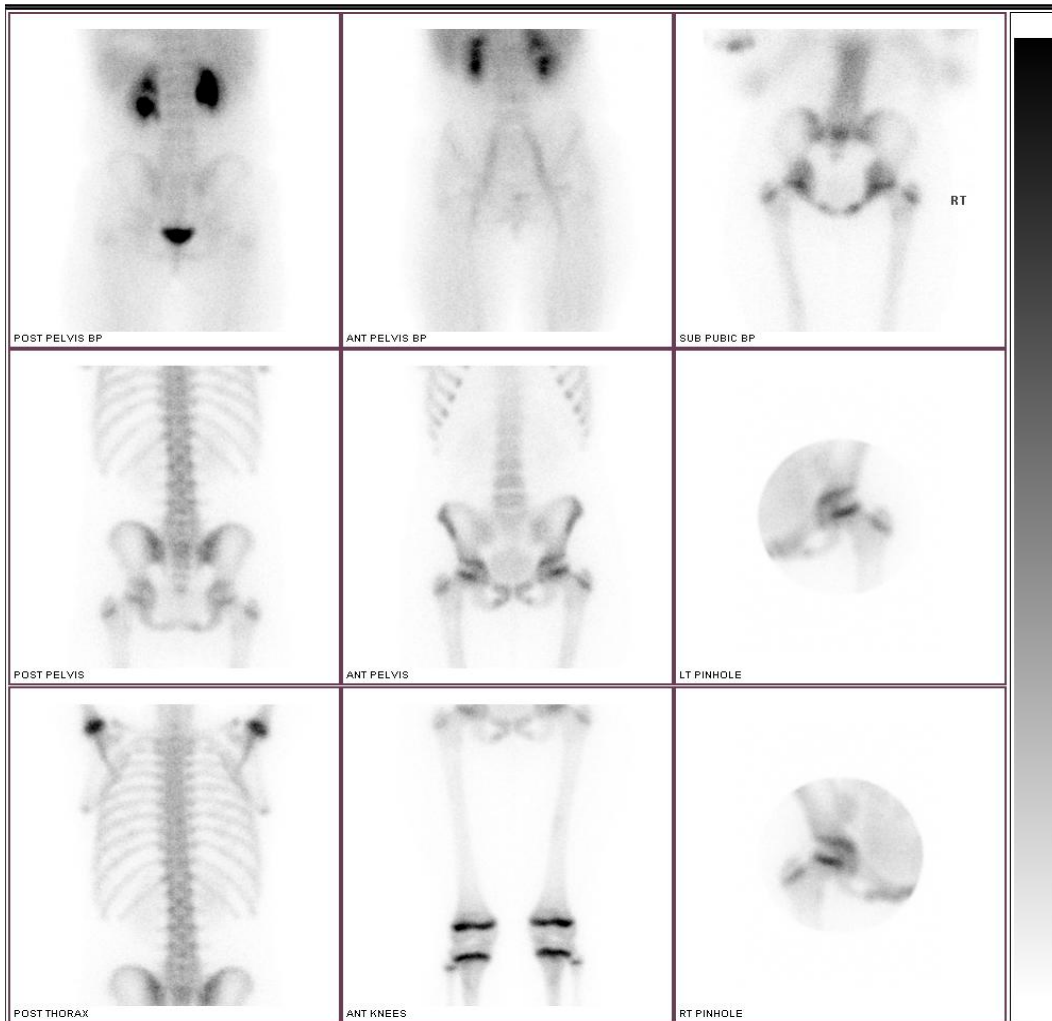


VULVAL LICHEN SCLEROSIS IN 8 YEAR OLD WITH ADJACENT BONE INVOLVEMENT – OSTEITIS PUBIS AND PERIOSTITIS



A 10 year old female presented with 18 month history of right episodic groin pain for which she had an appendectomy (normal), was treated for UTI's (no evidence) and had normal pelvic ultrasound. She was labelled "psychological problem".

Imaging showed mild hyperaemia of the pubis and adjacent bilateral superior and inferior pubic rami. Delayed images showed abnormal uptake on both sides of the pubis and adjacent superior and inferior pubic rami bilaterally, slightly worse on the right.