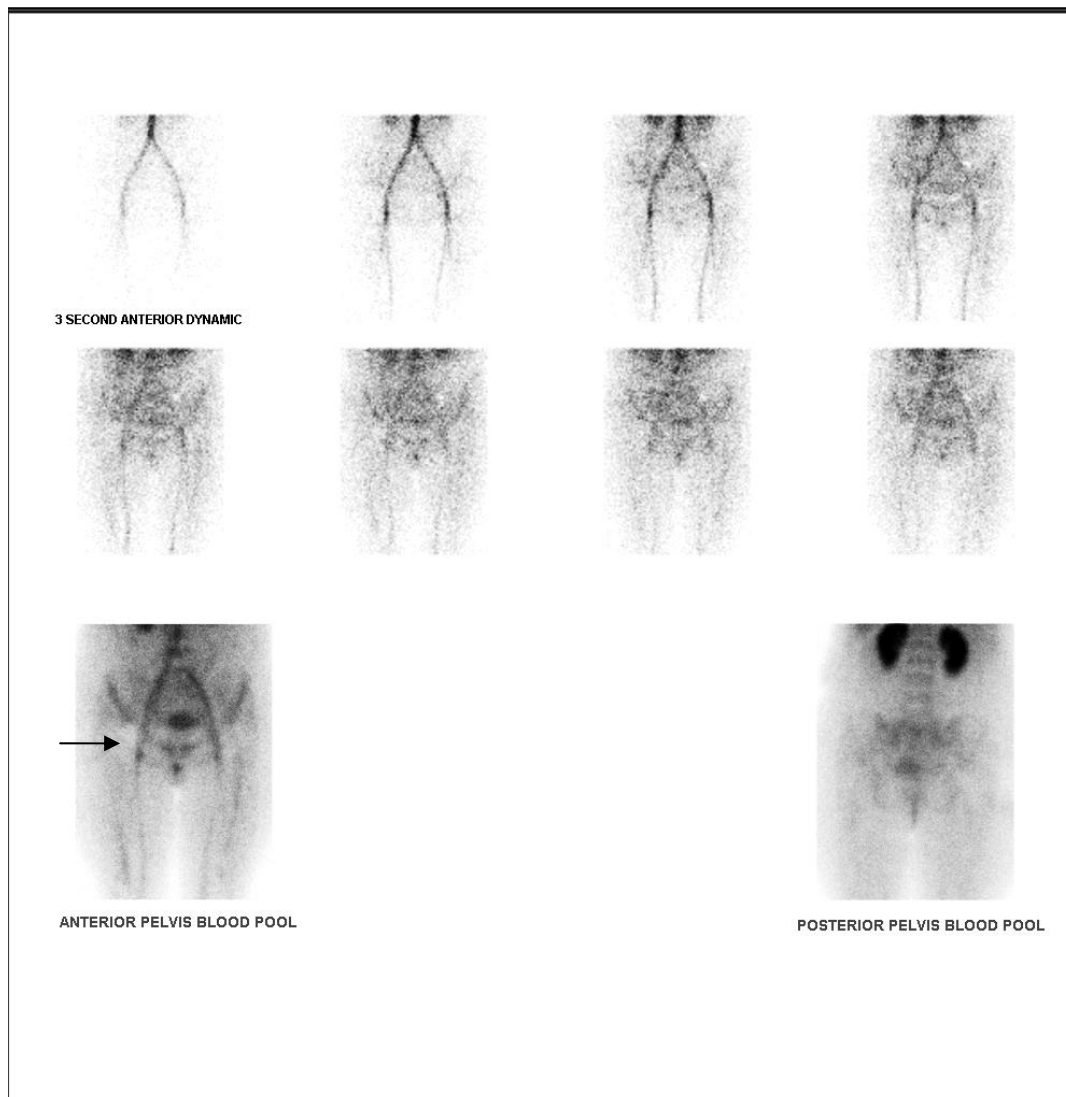
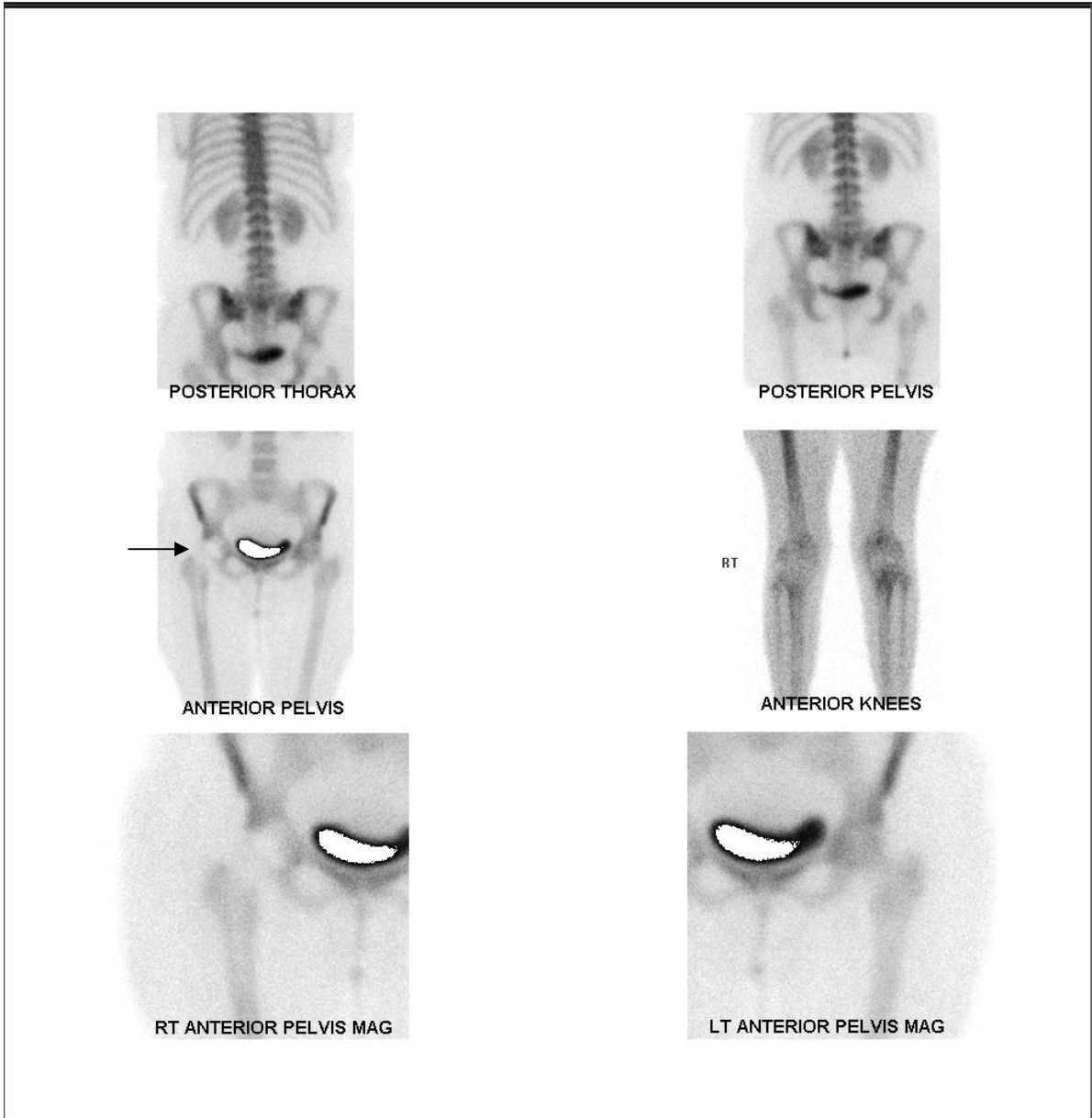


AVASCULAR NECROSIS OF RIGHT FEMORAL HEAD



A 35 year old female presented with an 8 month history of right hip pain and a background of alcohol abuse.

Early images (above), revealed hyperaemia of the right hip joint with a photopenic femoral head.



Delayed imaging revealed photopenia of the right femoral head, increased uptake by the hip in general and focal increased tracer uptake by the femoral head laterally, all indicating synovitis and early revascularisation of the lateral femoral head.