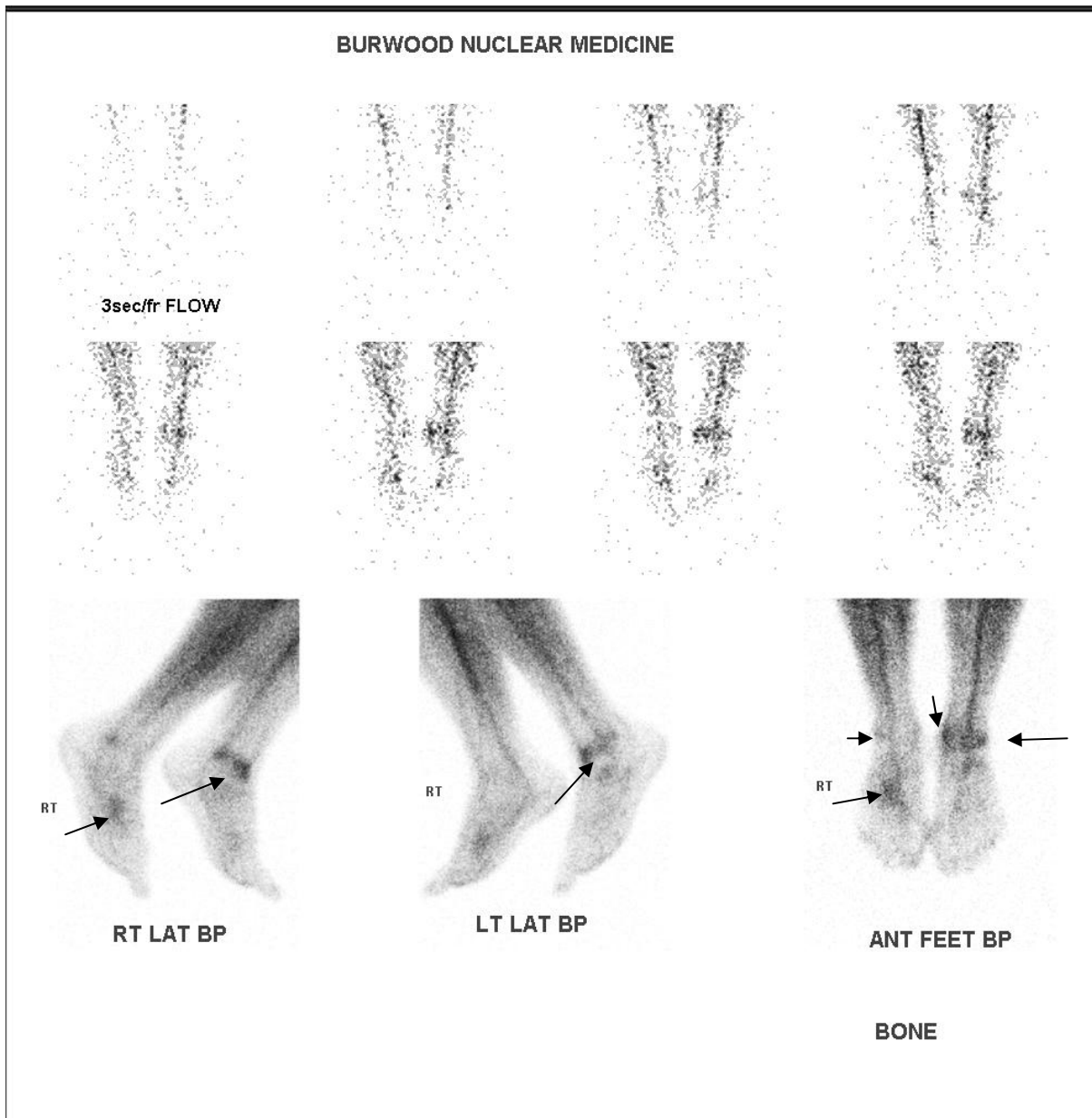


WIDESPREAD SPONDYLOARTHROPATHY



50 yo male presented with a painful and swollen left ankle 2 weeks after dancing. Past history included an impact injury to the left medial ankle, eight months prior. Also has pain and swelling to the right dorsal mid foot, right hand and right knee.

The early images show increased vascularity (arrows above) of the left ankle and right mid foot. There was fairly intense hyperaemia of the left ankle joint and the right mid foot, with hyperaemia of the left medial and right medial malleoli. There was also hyperaemia of the right knee, the left hip, the right 1st, 2nd & 3rd MCP and the right ulno-carpal joints (images not included).

In the delay images below there was inflammatory arthritis of the right 1st, 2nd & 3rd MCP joints, the right ulno-carpal, the left hip, the right knee, the left ankle and subtaloid and the right 3rd and 4th TMT joints. There was ligamentous enthesitis of the right lateral and left medial malleoli. There was degenerative arthritis of the medial left knee.

The overall pattern of asymmetric inflammatory arthritis & ligamentous enthesitis was consistent with sero negative spondyloarthritis. There may also be other associated features such as tenosynovitis, bursitis at various sites and sacroiliitis.

