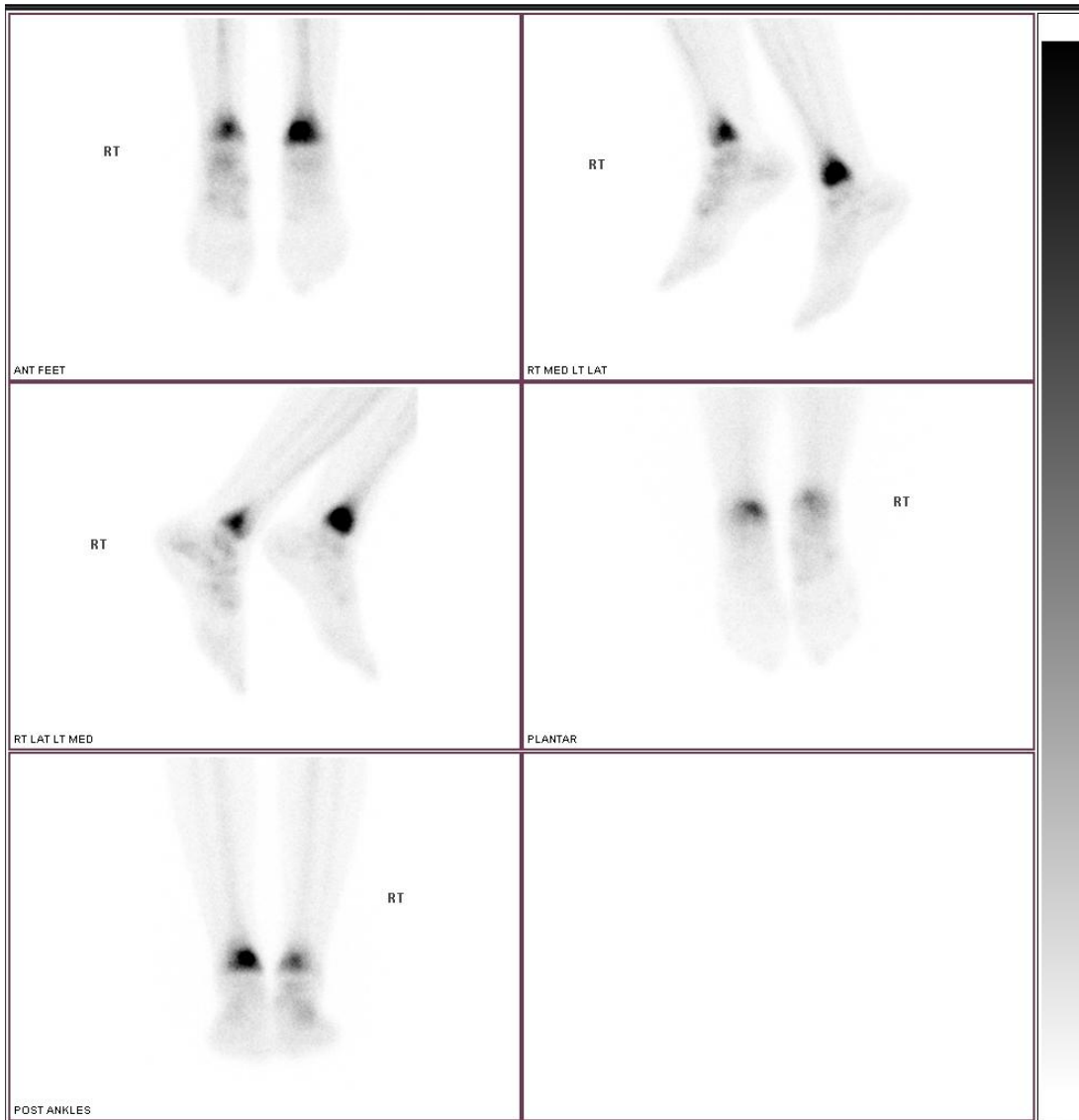


## HIGH GRADE LEFT/LOW GRADE RIGHT STRESS FRACTURES OF MEDIAL MALLEOLI



A 34 yo female presented with 3 day history of left medial ankle pain 3 weeks after commencing regular treadmill running at the gym.

Initial bloodpool images showed intense hyperaemia of the left medial malleolus and milder hyperaemia of the posterior right medial malleolus.

The delayed images above show a high grade stress fracture of the left medial malleolus and “bone bruising” of the adjacent tibial plafond and a low grade stress fracture of the posterior right medial malleolus.

Plain x-rays and CT scan on bone windows were all normal.